

Gargoylism in the African

REPORT OF A CASE

BY

J. E. P. THOMAS

M.B., M.R.C.P., M.R.C.P.E., D.C.H.

Locum Medical Specialist, African Hospital, Zomba.

It is a fairly common fault of doctors to be searching for "canaries" in the clouds when a common black crow is shouting at them from a nearby tree. Using the same simile, it is also common in African medicine to be so deafened by the noise of the crows that one misses the sweet call of the canaries.

The following is an interesting case of gargoylism in an African in Zomba:

CASE HISTORY

An African female, aged nine months, was admitted to Zomba African Hospital on 24th January, 1957. The striking feature at a glance was the rather large head, the circumference of which measured 20.5 inches. My first impression was that this was just "another hydrocephalus." Even when I saw a rather marked kyphosis I tried to explain it away as a "spina bifida and meningocele."

Even the finding of a large liver and spleen I was about to dismiss as "normal in Africans!"

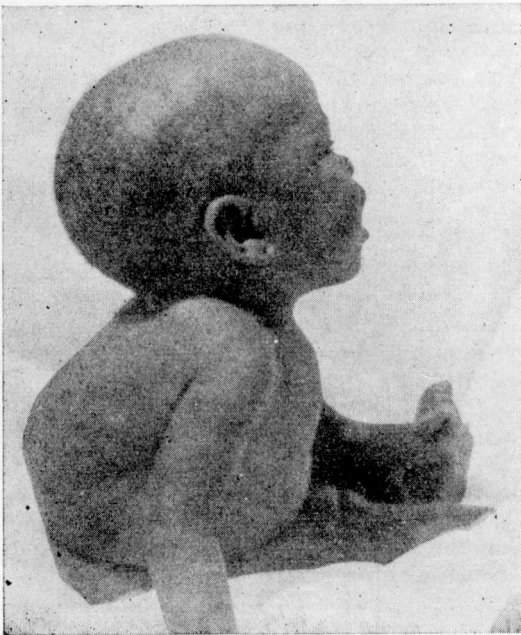

Fig. 1—The baby is propped up and this side view demonstrates the kyphosis, the large head flopping backwards, the slight frontal bossing, the prominent eyebrows and the rather squat nose.

Suddenly the bell rang and I saw before me an extremely ugly child, with a large head, frontal bossing, excessive eyebrows and a tough dry scalp of hair. The nose was squat and constantly discharging (Figs. 1 and 2). The child was mentally retarded in that at nine months it did not respond to its mother's overtures, could not hold its head up properly and could not sit unsupported.

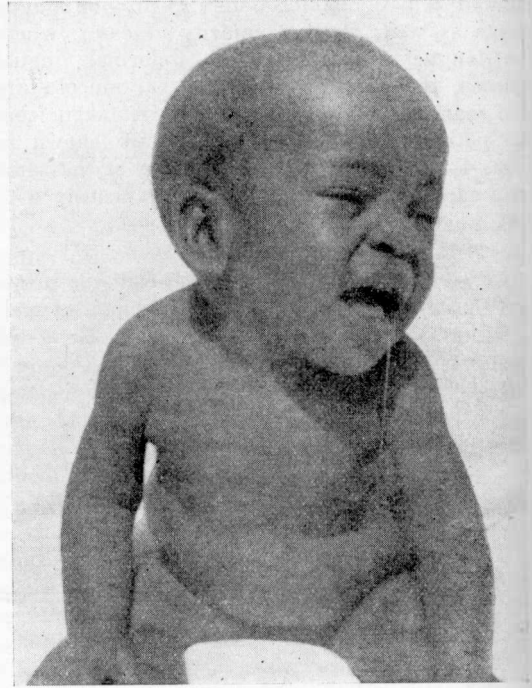


Fig. 2—A front view demonstrating the rather ugly features and the squat, discharging nose.

As mentioned earlier, it had a marked dorso-lumbar kyphosis and an enlarged liver and spleen, the former three finger-breadths and the latter two below the costal margin. No corneal opacities were detected and the mouth and tongue appeared normal. This was a first child and the mother maintained that none of the relatives were dwarfs or mentally subnormal. Thus clinically this seemed to be a typical case of gargoylism, and this diagnosis was confirmed on X-ray by demonstrating the characteristic vertebral deformity. The vertebrae were rounded, biconvex and with a peculiar hook-like process projecting inferiorly in place of the anterior half of the vertebral bodies (Fig. 3).

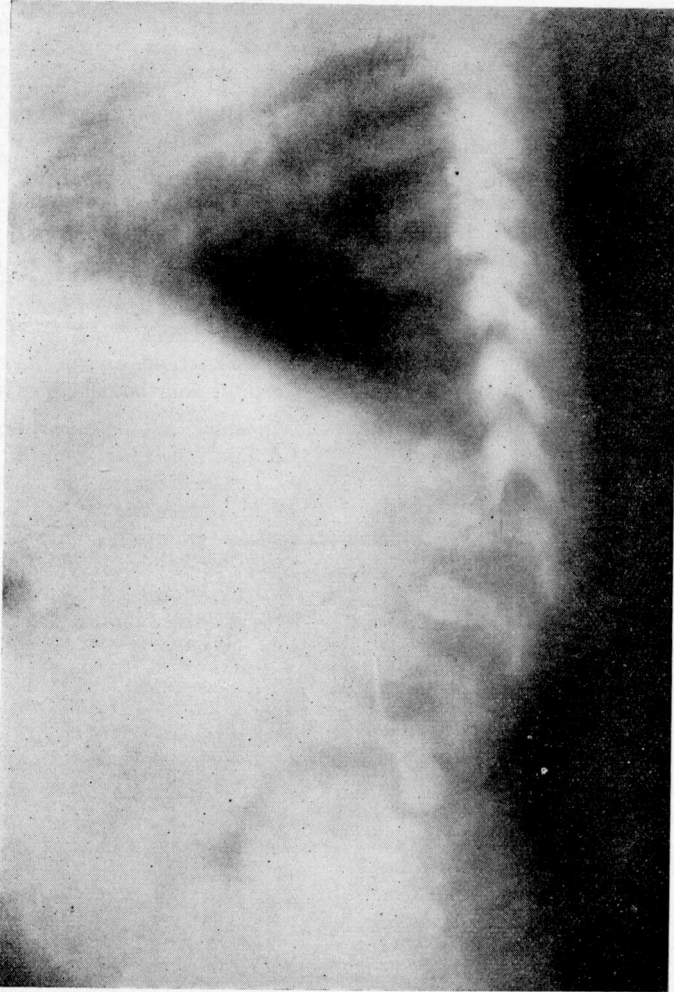DISCUSSION

This disease was originally known by various names such as Hunter-Hurler's disease, dysostosis multiplex, lipochondrodystrophy and appropriately named gargoylism by Ellis, Sheldon and Capon.¹

When fully developed, this condition has such a constant and bizarre association of abnormal

characters that it can definitely be classed as a disease entity, though the cause remains unknown. The genetic transmission of gargoylism has not been fully worked out, since nobody has yet collected a large enough series of well investigated family trees. There appear to be forms

to be a lipid substance, but evidence⁵ suggests that this is not the case and some have postulated a muco-polysaccharide. These abnormal deposits occur in bone, reticulo-endothelial cells such as liver and spleen, anterior lobe of the pituitary and corneae.



An X-ray demonstrating the dorso-lumbar kyphosis. The vertebrae are biconvex, the anterior part being nothing but inferiorly projecting hook-like processes.

of the disease with different genetic determinations, e.g., in most cases an autosomal recessive gene is responsible,² but a Norwegian³ and an English⁴ family were described which suggested a sex-linked recessive.

Pathologically the disease seems to be a storage disease, but the nature of the stored substance has not been settled. Originally it was thought

Clinically the full syndrome comprises coarse ugly features with a large abnormally-shaped head, excessive eyebrows and tough dry hair on the scalp; the bridge of the nose is depressed, with nasal discharge; there is a wide mouth and large tongue; opacities of the corneae are seen; there is a dorso-lumbar kyphosis, dwarfism and some limitation of the movement of the limb

joints; hepato-splenomegaly is common, as is mental retardation. *Formes frustes* do occur, however, and are seen especially in siblings whose brothers and sisters show the florid form.⁶

Radiologically the most typical changes are those in the vertebrae. Originally these were thought to be indistinguishable from Morquio's disease, but recent studies suggest that in the latter the vertebrae are flattened, biconcave and with a central projection; whilst in gargoylism the vertebrae are rounded, biconvex and with an inferior projection resembling a beak or hook-like process replacing the anterior half of the vertebral body. The long bones are stouter than normal, with accentuation of their ridges and markings. In severe cases all the epiphyses may be fragmented and deformed. They appear late and develop slowly. The widening and shortening of bones is often well seen in the metacarpals and phalanges. The skull is usually large though otherwise normal in most cases, but there may be evidence of pressure deformity with elonga-

tion of the cella turcica if osteoporosis has been severe.

Instances of this condition have been recorded throughout childhood and beyond puberty, but it is uninfluenced by treatment.

BIBLIOGRAPHY

1. *Quart. J. Med.*, 1936, 5, 119.
2. *Amer. J. Ment. Defic.*, 1942, 46, 298.
3. *Acta. Paediat.* (Uppsala), 1946, 33, 267.
4. *J. Neurol. Neurosurg. Psychiat.*, 1952, 15, 253.
5. *Arch. Dis. Childh.*, 1952, 27, 230.
6. *Arch. Dis. Childh.*, 1951, 26, 549.
7. SHELDON, W. *Diseases of Infancy and Childhood.*
8. *A Textbook of X-ray Diagnosis* by British authors.
9. ANDERSON. *Pathology.*
10. PRICE, F. W. *A Textbook of the Practice of Medicine.*

Acknowledgments

My thanks are due to the Director of Medical Services, Nyasaland, for his permission to publish this article, and to the staff of Zomba African Hospital for their helpful co-operation.