

The Urological Aspects of Bilharziasis in Rhodesia

BY

R. M. HONEY, M.B., F.R.C.S. (Ed.)

Consulting Urologist, Salisbury Hospitals Group;

AND

MICHAEL GELFAND, C.B.E., M.D., F.R.C.P.

*Consulting Physician, European and African Hospitals,
Salisbury.*

PART VI

Treatment of the Sequelae

Patients showing ureteric dilatation without stenosis of the lower third of the ureter frequently complain of aching pain in the iliac fossa on the affected side and not infrequently of colic. Of the 59 European patients in our series who had dilated ureters without evidence of stenosis, 11 suffered from colic and 27 from varying degrees of dull pain in the iliac fossae. Their ureters were dilated during the initial diagnostic procedure and many of them declared that it had relieved their pain for some months. They returned at regular intervals requesting to have instruments passed, although they were told that they had no stenosis. The manner in which instrumentation eased their discomfort has always puzzled us. We presume that it alleviates some superadded spasm.

Two of the patients with grossly dilated ureters suffered so much discomfort that the dilated segment of some 7 cm. length was excised and the proximal segment re-implanted in a new site in the bladder. On each occasion the patient claimed considerable relief from the procedure. It is, however, a step we do not recommend for this type of case unless there is considerable and persistent discomfort.

Up to the time of writing, no treatment has been carried out on those who have gross ureteric distortion and hydronephrosis without evidence of stricture or decreased bladder capacity. Twice was ileal replacement of the ureter offered as a treatment to the patient, but each time it was declined.

In most instances where dilatation exists without stenosis the symptoms are slight or absent and no therapeutic procedure should be contemplated. The patient is told that whilst he may experience vague iliac fossa pain permanently, surgery is unlikely to benefit him.

STENOSIS

The treatment of stenosis of the ureter depends on the stage, the degree and the position of the stenosis. The danger of stenosis is the same

as with any other obstruction, namely, hydronephrosis with eventual destruction of renal tissue.

Hydroureter and hydronephrosis responded to cystoscopic dilatation in only two patients (one aged 14 and the other 16) when the ureteric orifice was constricted by very recent organising granulation tissue. By dilating the stricture in them through the range of bougies from 4 Charrier to 9 Charrier at monthly intervals on three occasions, the granulation tissue was efficiently torn and this allowed relief of the stenoses, which have not recurred. One patient has been observed for three years and the other for six years.

In all others, dilatation was of no permanent benefit, as can be readily appreciated when the stenosis is the result of dense fibrous tissue (Fig. 28). If the lumen is of fine bore and the walls

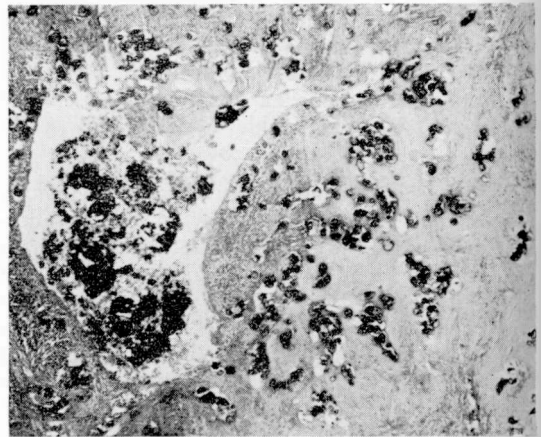


Fig. 28.—Microphotograph. Showing stenosed distorted ureteric lumen and grossly thickened fibrosed ureteric wall.

thick and unyielding, no bougies can possibly be forced through. On the other hand, if a bougie of reasonable size can be passed, dilatation without stenosis exists. Here our findings agree with those of Makar (1948). As previously stated, however, the passage of bougies has relieved dull aching pain in the iliac fossae in patients who have dilated ureters without stenosis. Cystoscopic dilatations have also been effective in dilating fibrous tissue contractions at the site of neocystostomy and on one occasion following cystoscopic meatotomy.

ERRATA: In the May issue of the *Journal* it is regretted that in the article on "The Urological Aspects of Bilharziasis in Rhodesia" two pages are transposed. For folio 205 read 206, and for 206 read 205.

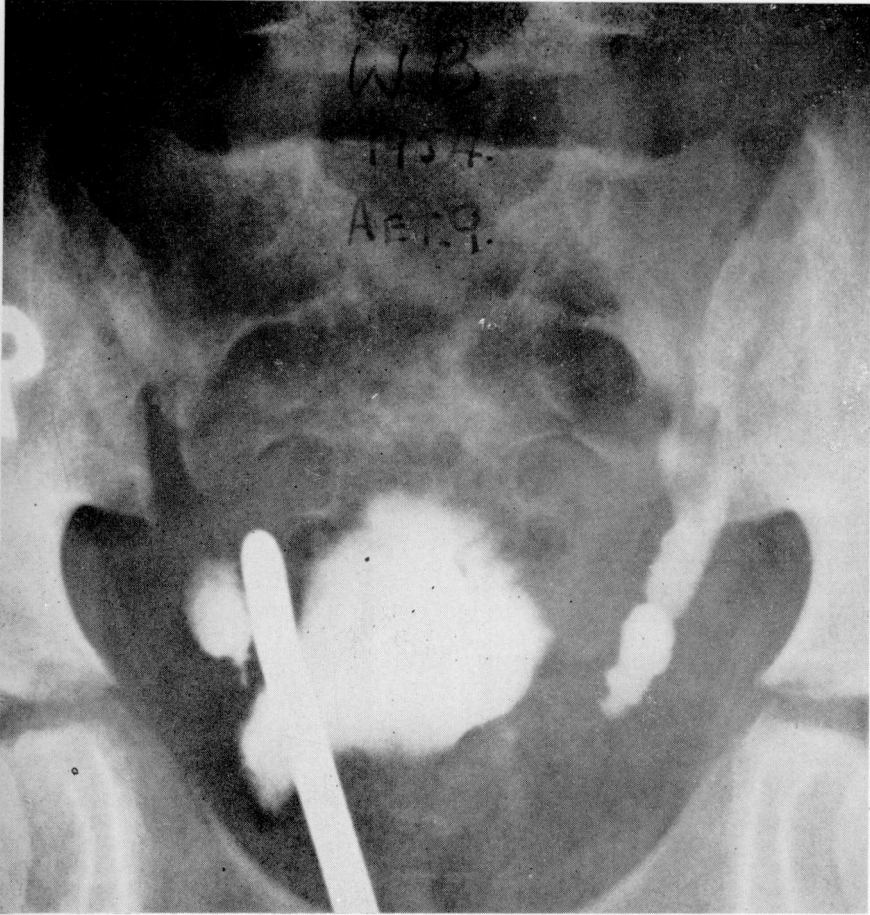

Fig. 29—European aged 10. Bilateral strictures extending 0.5 cm. proximal to the bladder wall. Treated by ureterocystostomy in continuity.

We employ some form of incision or excision for firm fibrous strictures. When the stenosis is confined to the intravesical portion of the ureter, the ureteric ridge is incised, the overlying mucosa, submucosa and muscle of the bladder wall being divided and the intravesical ureteric lumen opened into. To do this a diathermy knife through a McCarthy panendoscope is employed. The incision may run along the ridge, following up the line of the ureter from the orifice for about one centimetre, or a transverse cut is made about one centimetre above the orifice, all the tissues being divided until the lumen is opened. We have carried out this procedure on 72 ureters in 49 Europeans and 10 ureters in 27 Africans. Patients are asked to report back in six weeks, when they are

examined cystoscopically to ascertain if the incision was effective in overcoming the stenosis. One incision each was sufficient in 68 out of the 72 European ureters and in 39 of the 40 African ureters operated upon. In three European and one African ureter a second incision was necessary, as the narrowed portion involved the whole length of the intramural ureter.

High incisions which divide the overlying bladder wall over practically the whole length of the intravesical ureter leave a gaping hole which never closes. These patients show reflux of dye up the ureters in a micturating cystogram and they complain of some ache in the loin when the bladder is full and while micturating, but we have seen no renal damage ensuing from this in any patient, and some have been observed

for 20 years. We have found evidence of reflux after meatotomy in only seven of the 112 ureters treated by this procedure, and in them the incision was longest and deepest.

When the stenosis lies in that part of the ureter outside the bladder wall, treatment depends on the position of the stricture. A good X-ray clearly showing the degree and site of the stenosis should first be obtained. If the narrowing is immediately outside the bladder, it is tackled by open transvesical approach. The ureteric lumen, however fine, is followed up through the open bladder until the dilated portion is reached and a mucosa-to-mucosa junction between the ureteric and bladder mucosa effected. This procedure again leaves the ureter without a valve and allows a vesico-ureteric reflux, especially on micturition. We have carried out this operation on both ureters in only one patient—a child 10 years old (Fig. 29).

We have never employed forceful dilatation through the open bladder. On remembering the thickness and fibrous nature of the ureteric walls we do not see how a lasting success can follow this method of treatment (Fig. 30).

When the stenosis is beyond 1 cm. from the bladder wall and within 7 or 8 cm. (Figs. 31 and 32), the distal stenosed segment is excised and the proximal portion of the ureter is re-implanted into another site in the bladder. The ureter, however, is not pulled obliquely through the wall in the original or new site, as suggested by Makar (1948), as there has never been sufficient length of ureter to do this without tension, and the ureter above the stricture is usually dilated and thick-walled and impossible to bury obliquely in a bladder wall of normal thickness.

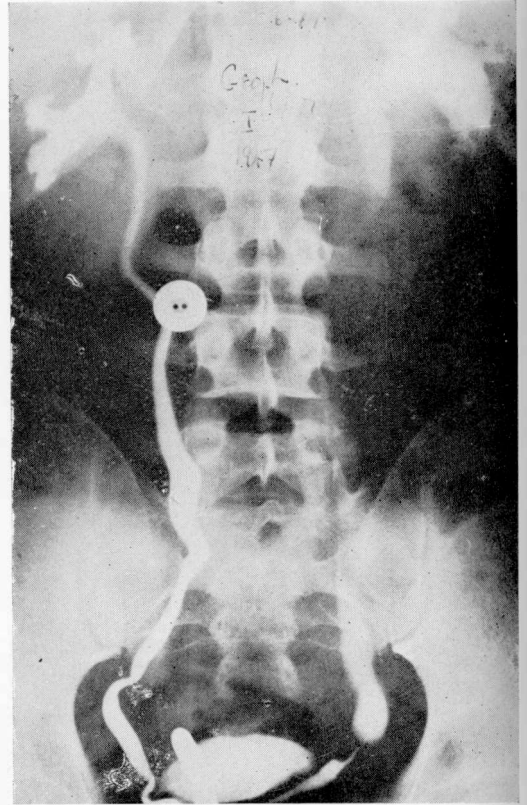


Fig. 31—European aged 23. Retrograde uretero-pyelogram showing stricture 5 cm. proximal to bladder wall. Treated by ureterectomy of distal segment and neocystostomy.

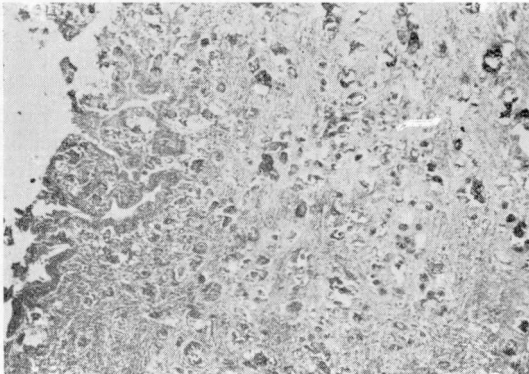


Fig. 30—Microphotograph of thickened fibrosed ureteric wall.

Excision and neocystostomy were carried out in this series in 14 cases involving 15 ureters. The first case was operated on in 1940, and from then until 1950 the double flap method of anastomosis was used. A stab wound was made in the bladder at a convenient spot above the original orifice and the proximal ureteric segment drawn through, split for approximately 5 mm. and the two flaps so formed sutured to the bladder wall. In the first two patients a splinting tube was employed, which was brought out through a separate incision in the bladder alongside a de Pezzar catheter. Both these patients developed stenoses at the site of the neocystostomy. One required dilatations and the other had a secondary procedure carried out elsewhere. By 1950 we had operated on a further six ureters in five patients, using the double flap technique without a splinting tube. One developed a stenosis which required to be dilated periodically. Other observers are also

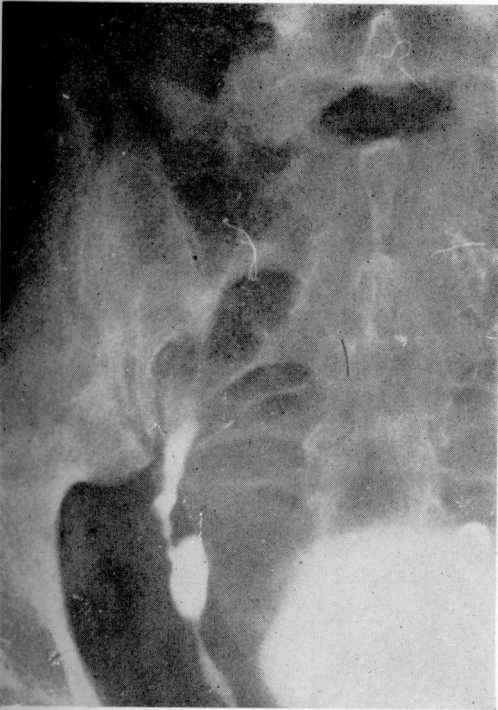


Fig. 32—European aged 32. Stricture 6 cm. proximal to bladder wall. Treated by ureterectomy of distal segment and neocystostomy.

doubtful on the benefit of using a splinting tube. Makar (1948) advocates the use of a splint, where Sayegh (1950), Henderson (1953) and Hamm and Weinberg (1955) condemn it. Since 1950 we have operated on seven ureters in seven patients. In four we used a mucosa-to-mucosa apposition of ureteric and bladder walls, after making an incision in the bladder about 0.75 cm. long. One healthy ureter was buried subperitoneally in a tunnel, the others being too thick to be treated in this way. In none of these has stenosis occurred at the neocystostomy site.

In one European patient the segment of diseased ureter which had to be excised left an upper healthy ureter too far separated from the bladder to allow anastomosis without the use of a tube formed by a bladder flap (Fig. 33). A bladder flap tube was also employed in a secondary operation which was required on account of a stricture which had formed at the ureterovesical junction subsequent to an operation carried out elsewhere at which a primary bilharzial stricture had been excised and neocystostomy carried out.

In one European the diseased segment of the lower ureter had multiple strictures which necessitated excision of so much ureter that neocystostomy, even by the bladder flap method, was not feasible. The gap between healthy ureter above and bladder below was bridged in him by employing a length of isolated ileum (Fig. 34).

In every patient on whom excision and neocystostomy has been carried out, vesico-ureteric reflux has occurred on micturition and when the bladder was full. It did not occur when stenosis was present at the neocystostomy site, but occurred in these patients once the stenosis had been relieved. Makar (1948) is not in favour of this method of re-implantation above the site of the original orifice without giving the terminal ureter its fully oblique normal course. It would be interesting to know if the technique he uses obviates vesico-ureteric reflux.

The blood pressure was not elevated in any of our patients with vesico-ureteric reflux.

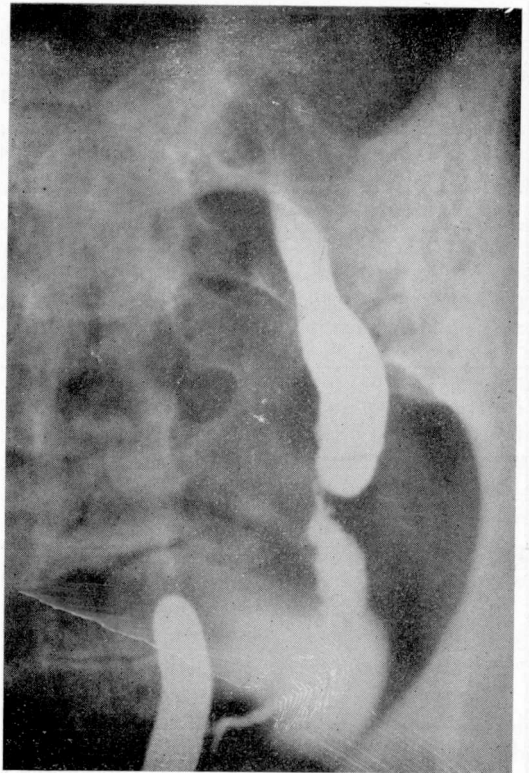


Fig. 33—European aged 13. Stricture 6 cm. proximal to bladder wall. Treated by excision of diseased segment and neocystostomy by use of a bladder flap.

In two European patients, in whom the stenosis was higher up the ureter in a situation which precluded excision and re-implantation, we excised the strictured segments and, spatuling the ends, carried out an end-to-end anastomosis. The ureters above and below these isolated strictures were sufficiently healthy and patent to allow of this procedure.

NEPHRECTOMY

This operation was performed in two Europeans: in one it was indicated because of an infected hydronephrosis above a stricture of the intravesical ureter, and in the other following a pyonephrosis which had developed after a bilharzial stricture had been excised at another hospital.

A nephrectomy was carried out on three Africans. In two of them the kidney was destroyed by calculi forming above strictures of the ureter in the bladder wall, and in the other two by massive hydronephrosis above a stricture situated in the middle third of the ureter.

RESULTS OF TREATMENT OF URETERIC STENOSIS

Clinically, the long-term results have been satisfactory. If hydronephrosis existed before elimination of the stricture, it invariably improved and the kidney returned to normal (Figs. 35 and 36). After elimination of the stenosis the patient no longer complained of colic.

If the ureter was dilated above the stricture the dilatation frequently diminished and the lumen returned to normal after operation. In

Table XI

TABLE GIVING SUMMARY OF TREATMENT

	Europeans	Africans
A. STRICTURE—		
1. Dilatation only. Cystoscopic (only in early granulation tissue which tore easily). Ureters	2	—
2. Dilatation only. Cystoscopic. To ease symptoms in dilated ureters which are not stenosed	4	—
3. Dilatation. Cystoscopic. Following neocystostomy and meotomy	3	—
4. Dilatation only. Open	—	—
B. MEATOTOMIES—		
1. Cystoscopic. One Occasion: Patients	46	26
Ureters	68	39
Two Occasions: Patients	3	1
Ureters	4	1
2. Open. Patients	1	1
Ureters	2	(Associated with ureteric calculus) 1
C. EXCISION AND NEOCYSTOTOMY—		
Patients	14	—
Ureters	15	—
Technique of Neocystostomy. Ureters split	8 in 7 patients	—
Nisbet	4	—
Bladder flap	2	—
Ileal loop replacement	1	—
Stenosis following re-implantation (a) done by us	2	—
(b) done elsewhere and subsequently examined by us	2	—
D. EXCISION AND END-TO-END ANASTOMOSIS—		
Patients and ureters	3	—
E. NEPHRECTOMY	2	3
F. ILEOCYSTOPLASTY	1 (Coloured)	8

others there was no diminution of the dilatation (Fig. 37). We assume that when the lumen returned to normal the ureteric wall was normal or only slightly involved in bilharzial fibrosis, and in those in whom the ureter remained grossly dilated the wall was extensively diseased. Those with grossly dilated ureters frequently complain of a persistent dull ache in the iliac fossa even after the stricture has been eliminated. Many of those who have vesico-ureteric reflux experience discomfort in the loin when a full bladder is emptied (Henderson, 1953).

Two patients who underwent excision and neocystostomy have slight persistent urinary infection. In all the patients with reflux the ureter, pelvis and calices can be seen to dilate considerably during micturition, but in the rest-

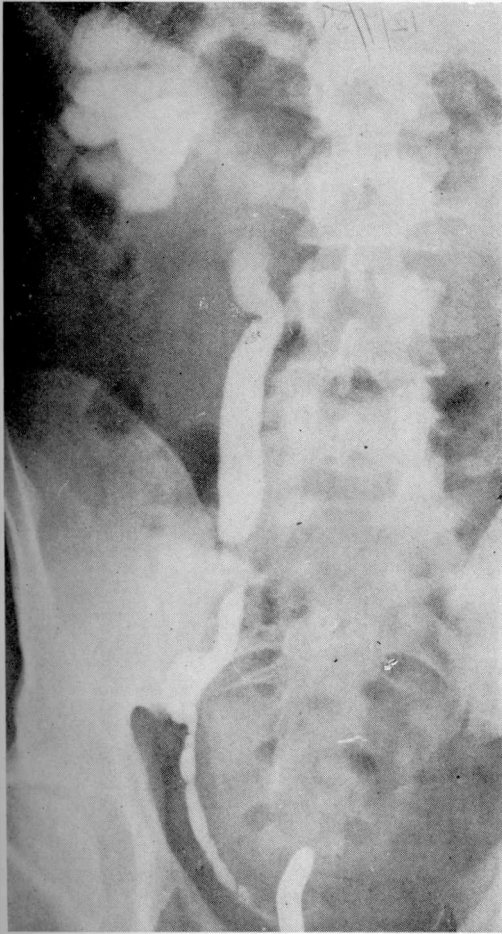

Fig. 34—European aged 34. Multiple strictures of distal ureter. Treated by excision of diseased segment and ileal replacement.

ing phase, when intravesical pressure is reduced, they are within normal limits.

TREATMENT OF THE CONTRACTED BLADDER

In bilharzial interstitial cystitis the bladder wall is usually very thick and the capacity of the organ is often markedly decreased. There is usually as well a superimposed secondary infection and it is wise to treat this before contemplating an operative procedure. Elimination of the infection may temporarily increase the bladder capacity, with corresponding decrease in the frequency and urgency of micturition, and in the border-line cases the necessity for an operation may be eliminated. A course of arsenical drugs such as N.A.B. is also prescribed in case the occasional patient may be suffering from an undiagnosed superadded abacterial cystitis. This procedure has considerably helped three patients.

For this type of case Sayegh (1950) and Sayegh and Dimmette (1956) advised ureterocutaneous transplantation. They reported as having tried ileo-cystoplasty in 1956 on two patients without success, due to poor healing of the tissues in which bilharzial ova are deposited.

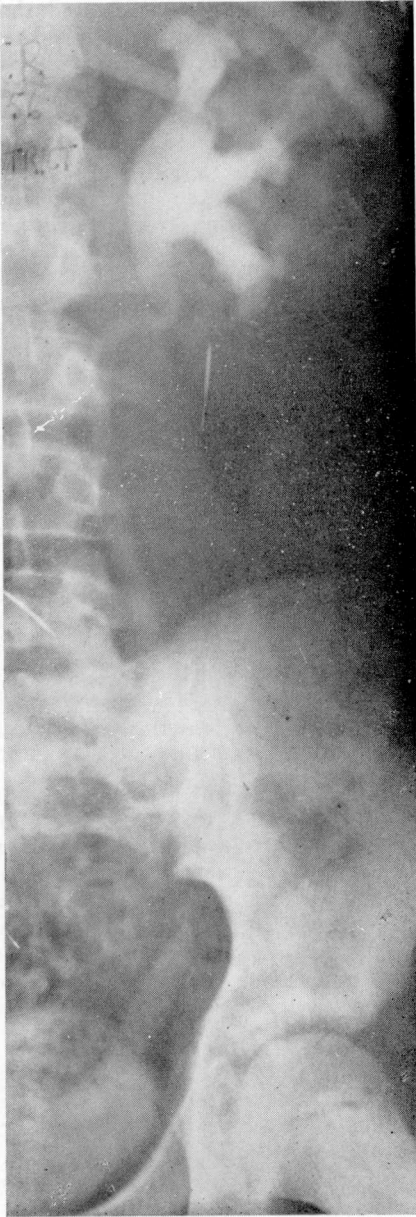Since 1955 we have carried out the operation of ileocystoplasty on this type of case (Honey and Gelfand, 1956). Bladder neck stenosis or urethral stenosis if present as well is treated at the same time, as any obstruction at the outlet of the bladder would prevent healing of the syrapubic sinus after ileocystoplasty.

The point at which bladders with fibrous, non-expansive walls, reduced capacity and high tone cause ureterectasis and renal damage varies considerably. Some bladders having a 250 ml. or even 200 ml. capacity, with marked frequency, show no material ureteral or pelvic dilatation, while others of similar capacity are accompanied by reflux and dilatation, and some show ureterectasis and pyelectasis without evidence of reflux.

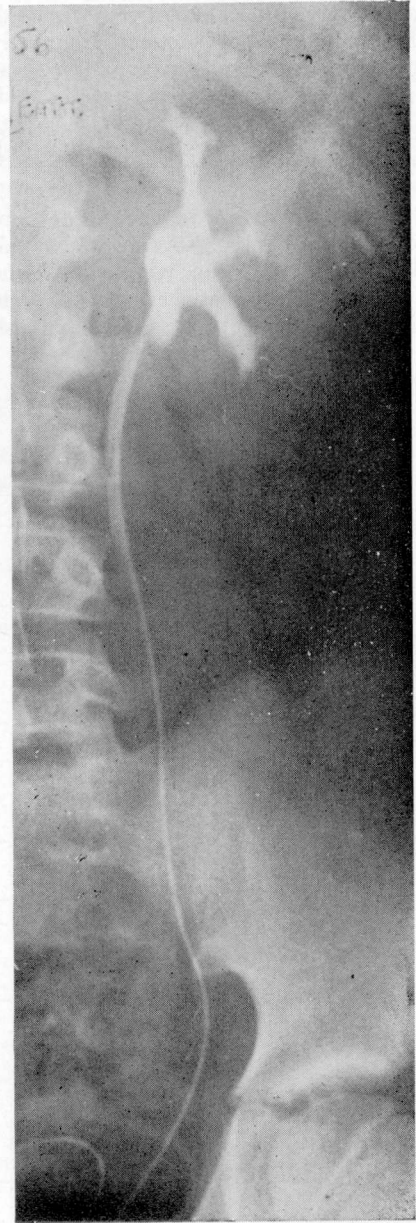Once the ureters and pelves are grossly dilated and are associated with vesico-ureteric reflux, it is impossible to gauge accurately the capacity of the bladder, as bladder, ureters and pelves may be regarded as being one continuous cavity.

The aim is to carry out in these small bladders some operation which would enlarge their capacity before renal damage has occurred. Any patient with a contracted bladder who complains of a greatly increased frequency of micturition which does not respond to antibiotic

Fig. 35—European aged 13. Submucosal fibrosis giving pinpoint ureteric meatus.



A. Intravenous pyelogram showing dilatation of ureter and hydronephrosis.



B. Retrograde pyelogram six weeks after cystoscopic meatotomy.

and arsenic therapy, and who has a bladder capacity below 250 ml., is advised to undergo an ileocystoplasty.

In the present series we advised the operation 25 times and carried it out on eight Africans. We have used different techniques, but owing to the difficulty of following up these cases for any length of time we can give no definite opinion as to which technique would be the most successful.

In some there is a combination of fibrotic bladder and ureteric stenosis. In this event the ureter above the stricture is implanted by mucosa-to-mucosa suture into the open end of the isolated ileal segment. In the majority the bladder wall is greatly thickened up to 1.5 or 2.5 cm., and it is very difficult to anastomose the ileal segment to this thick fibrous structure. Using interrupted sutures placed close together, however, we have been successful in all cases in effecting a suitable anastomosis.

The short-term post-operative results have been satisfactory. The patients have been able to hold their urine for reasonable periods and micturition seems normal. The bladder capacity is reasonably increased and intravesical pressure falls (Fig. 38). The urine, however, remains infected for long periods.

MORTALITY

There was one fatality after an ileocystoplasty had been carried out. The patient developed intestinal obstruction on the seventh day after operation. The patient was unco-operative and refused a second operation, as well as measures aimed at intestinal decompression. At autopsy a haematoma was discovered in the submucosa at the site of an end-to-end ileal anastomosis. This led to acute intestinal obstruction. The ileocystoplasty was healing satisfactorily.

VESICAL NECK FIBROSIS

We have only encountered this lesion on three occasions. One in a Eurafrikan and two Africans. All were treated by transurethral resection, using a Nesbit resectoscope. Their ages were 48, 38 and 32. Bilharzial ova were demonstrated in the tissue resected, which suggests the possibility that bilharziasis may have been the cause of the lesion.

VESICULITIS

It is rare in our experience to have symptoms caused by bilharziasis of the vesicles. There were three cases in our 300 European patients.

Two complained of haematospermia and two of deep-seated perineal pain, worse after ejaculation. In the latter two, one vesicle in each was caked and hard and was removed through the perineum. In the other patient, who complained only of a haematospermia, the diagnosis of bilharzial vesiculitis was made cystoscopically on observing the presence of gross bilharzial disease of the bladder base. His haematospermia cleared up after sodium antimony tartrate had been administered.

SUMMARY

(1) The urological aspects of bilharziasis in 300 Europeans and 100 Africans are described in this study, which was carried out in the Salisbury European and African hospitals.

(2) As there are a number of important differences in the form assumed by the disease in the Europeans and Africans, it is considered preferable to refer to "European bilharziasis" and "African bilharziasis."

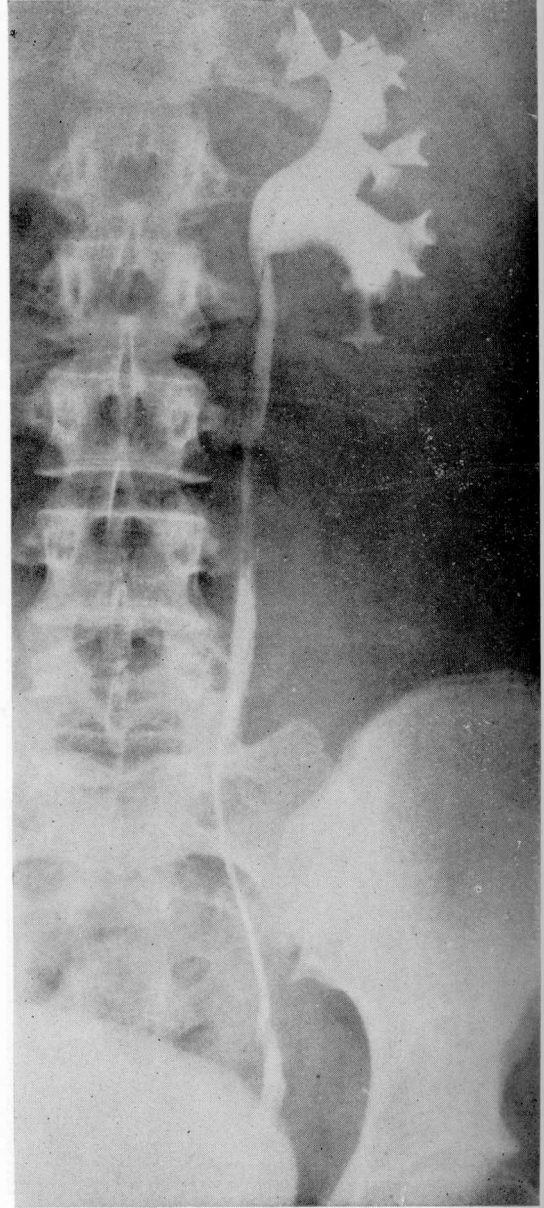
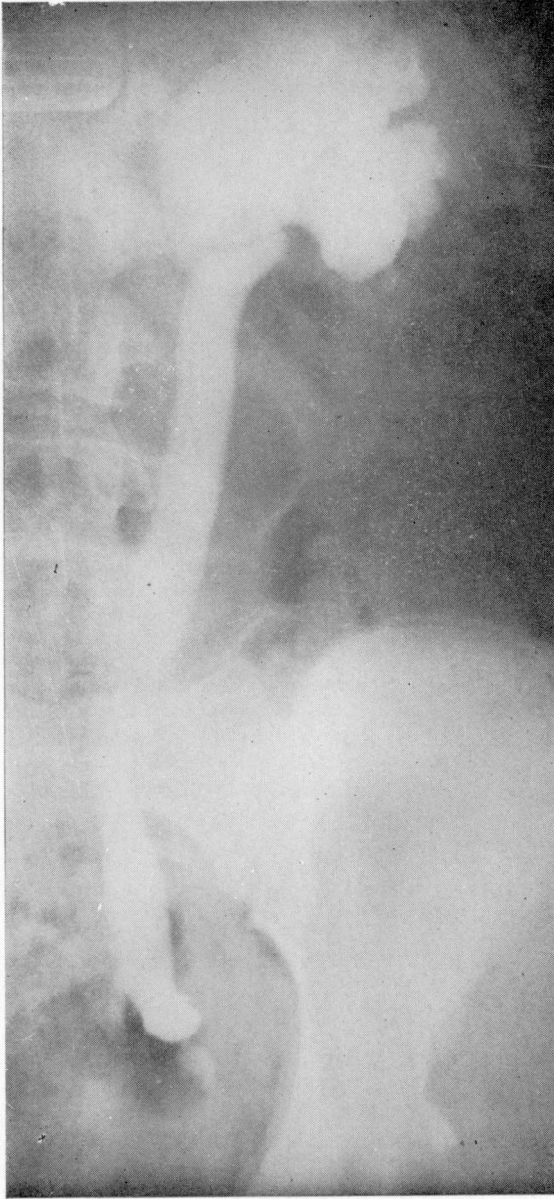
(3) The pathological effects of the disease in the bladder and ureter are described. In the European the tubercle is the most common finding, but in the African the sandy patch and bilharzioma and papilloma are more typical, indicating a much longer infestation.

(4) In the presence of extensive disease the capacity of the bladder is reduced and the intravesical pressure rises, producing back pressure on the pelvis of the kidney and hydronephrosis. Increased frequency of micturition is the principal feature of a fibrotic and contracted bladder.

(5) A vesical biopsy may occasionally reveal the presence of ova when the bladder mucosa appears normal. The value of this examination is small as compared with that of rectal biopsy.

(6) Fibrosis of the ureteric wall leads either to stenosis or dilatation or to both. The lowermost portion of the ureter is the most likely site affected. Disease of the ureter is generally accompanied by changes in the bladder itself. Rarely does the bladder escape. Stricture or dilatation of the ureter shows itself in pain, often colicky, but the spasm is less severe than that met with in calculus. Fibrosis of the ureteral wall interferes with its proper contractility and so there may be increased back pressure in the kidney. When the ureter is stenosed the part above dilates and the pelvis and calices on that side follow suit. When the intravesical pressure is high and the ureteric orifice distorted, reflux occurs with micturition, with consequent increase

Fig. 36—European girl aged 13.



A. Hydronephrosis and ureteric dilatation above a stricture of the ureter (seen in Fig. 33).

B. Retrograde pyelogram four months after excision and neocystostomy by bladder flap.

of pressure on the kidneys. This gives rise to hydronephrosis.

(7) Calculi are rarely encountered in the disease.

(8) Acute secondary infection in a bilharzial bladder is rare in the European and African. In the later stages of bilharziasis a mild infection with *E. coli* is not uncommon, but an acute superimposed cystitis is rare.

(9) Carcinoma of the bladder in association with bilharziasis was not encountered in the European, but in the African the two are not uncommonly seen together. A younger age group too is affected by cancer than in the European, in whom it is ordinarily encountered at a much later stage in life. The much heavier infestation of the bladder in the African probably accounts for these differences.

(10) Next to the tubercle, the most frequent finding on cystoscopy is the pallor or ground-glass appearance of the mucosa.

(11) Although ova may be deposited in the seminal vesicles, prostate, testis and epididymis, involvement of these organs rarely gives rise to symptoms.

(12) The ureteric orifices are commonly altered in shape and position, often being rounded, invisible or of the golf hole type.

(13) Calcification of the bladder is practically confined to Africans. Its presence need not denote an inelastic bladder wall or one of reduced capacity, although usually its presence is associated with a bladder of reduced capacity. Calcification of the ureter is less frequently found, and then only in association with that in the bladder.

(14) The earliest sign of ureteric involvement on intravenous pyelography is persistent filling of lower segment. A stenosis or dilatation may be present, but this can only be satisfactorily proven by retrograde pyelography. Marked dilatation of a ureter is usually associated with either stenosis or a bladder of small capacity. Whereas one-third of our African series showed a reduced bladder capacity associated with a high intravesical pressure, less than 1 per cent. of the European cases had a decreased bladder capacity. Reflux is usually caused by the high pressure created by the contracted bladder. Reflux up a ureter was demonstrated in 9 per cent. of our African series, but in none of the Europeans.

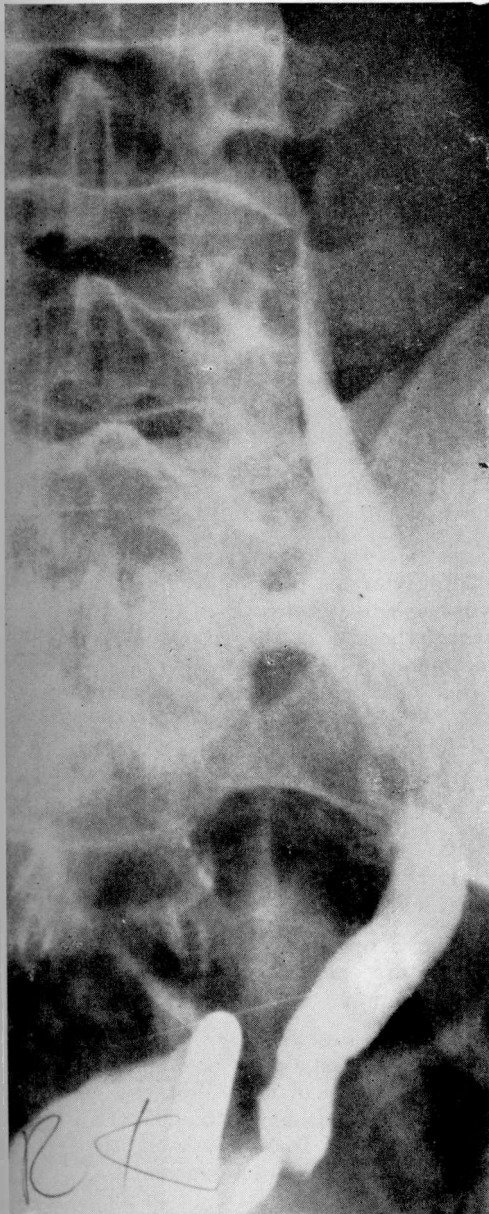


Fig. 37—European aged 37. Dilatation of ureter persisting after a stricture of the intramural ureter has been eliminated by cystoscopic meatotomy.

(15) The efflux of indigo-carmin when injected intravenously is of help in distinguishing between stricture and dilatation of the ureter. When stenosis is present the dye emerges in a jet of fine bore, but in the presence of dilatation it merely trickles out.

(16) Over 85 per cent. of strictures were found in both series either at the level of vesical submucosa or in the intravesical ureter up to 1.5 cm. from the orifice. A lesser number lay within 2.5 cm. of the orifice in the extravascular portion of the ureter.

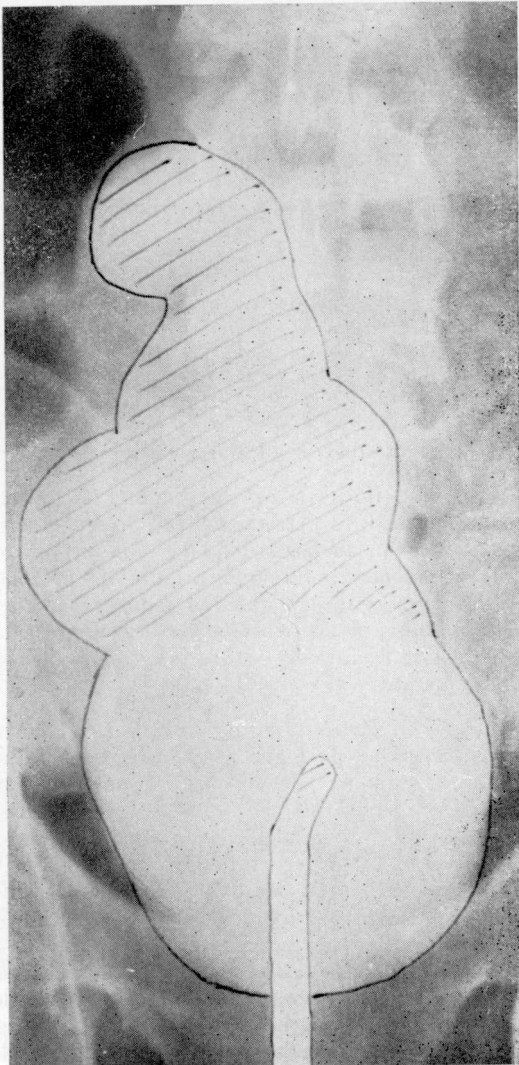


Fig. 38—African aged 34. Cystogram showing increased capacity after ileocystoplasty.

(17) A ureteric orifice may appear normal, yet will only admit an instrument with difficulty because of the unyielding nature of the bladder wall and unusual orientation of the orifice. When a bougie cannot be passed into the orifice a cystoscopic meatotomy is performed. Should the bougie be held up along the length of the ureter an obstruction is present and a ureteropyelogram is done in order to outline the lumen more clearly. This will enable a stenosis or an irregularity in the wall to be differentiated.

(18) When there are ureteric lesions the bladder mucosa also shows typical lesions, but occasionally the bladder mucosa appears normal.

(19) In 22 per cent. of Africans in the series, dilatation of the ureter was found. This may occur in the presence of a contracted bladder with high tension or the bladder capacity may be normal.

(20) The frequency with which stricture and dilatation of the ureter occurs in the series is given.

(21) Fourteen per cent. of the Europeans had hydronephrosis (always associated with stricture), whereas in the African hydronephrosis was found in 54 per cent. due to stricture, high tension bladder or dilatation of the ureter.

(22) Many European patients with stenosis in the lower third of the ureter were treated by dilatation, many of them claiming temporary relief from the pain.

(23) Occasionally, when there is much discomfort, the dilated and diseased portion of the ureter may be excised.

(24) If hydronephrosis occurs in the absence of stricture, no treatment to the ureter is recommended.

(25) The best treatment for early stenosis of a ureter is dilatation, but when the stenosis is due to excessive or dense fibrous tissue reaction, incision or excision of the affected segment is employed. The frequency with which this procedure was carried out is given.

When the stenosis is just outside the bladder wall the bladder is opened and a mucosa-to-mucosa junction effected between bladder and ureter. A stricture situated beyond 1 cm. from the bladder and within 7 or 8 cm. is excised and the proximal portion of the ureter reimplanted into another bladder site.

(26) Excision and uretero-ileo-neocystostomy were also carried out.

(27) Nephrectomy was also necessary occasionally.

(28) For the contracted bilharzial bladder, ileocystoplasty deserves a further trial and the results of this procedure are discussed.

REFERENCES

- ALVES, W., WOODS, R. W. & GELFAND, M. (1955). *C. Afr. J. Med.*, 1, 166.
- BENNIE, I. (1949). *S. Afr. med. J.*, 23, 97.
- BUNTS, R. C. (1958). *J. Urol.*, 79, 747.
- CAMPBELL-BEGG, R. (1946). *Brit. J. Urol.*, XVIII, 176.
- DIMMETTE, R. M., SAYEGH, E. S. & SPROAT, H. F. (1955). *Surg. Gyn. & Obst.*, 101, 721.
- DIMMETTE, R. M., SPROAT, H. F. & SAYEGH, E. S. (1956). *J. Urol.*, 75, 680.
- FRASER ROSS, W. (1949). *Brit. med. J.*, 2, 368.
- GELFAND, M. (1948). *Brit. med. J.*, 26th June.
- GELFAND, M. (1948). *Amer. J. trop. Med.*, 28, 563.
- GELFAND, M. & HONEY, R. M. (1953). *S. Afr. med. J.*, 27, 326.
- HAMM, F. C. & WEINBERG, S. R. (1955). *J. Urol.*, 73, 475.
- HAMM, F. C. & WEINBERG, S. R. (1956). *J. Urol.*, 75, 43.
- HENDERSON, D. ST. C. L. (1953). *Brit. J. Urol.*, 25, 3.
- HIGGINS, T. T., WILLIAMS, D. I. & NASII, D. F. F. (1951). *The Urology of Childhood*.
- HONEY, R. M. & GELFAND, M. (1956). *C. Afr. J. Med.*, 2, 1.
- HUTCH, J. A. (1958). *The Uretero Vesical Junction*.
- KIRKALDY-WILLIS, W. H. (1946). *Brit. J. Surg.*, 34, 189.
- MAKAR, N. (1948). *Brit. J. Surg.*, 36, 148.
- MAKAR, N. (1955). *Urological Aspects of Bilharzia in Egypt*. S.O.P. Press, Cairo.
- MAKAR, N. (1957). *Brit. J. Surg.*, 45, 240.
- MILLER, C. D., BRANCATO, F. P. & MUELLING, R. J. (1954). *J. Urol.*, 72, 197.
- MORLEY-SMITH, F. & GELFAND, M. (1958). *C. Afr. J. Med.*, 4, 287.
- NORING, O. (1958). *J. Urol.*, 79, 701.
- ORR, L. M. (1950). *J. Urol.*, 63, 1043.
- PRENTISS, R. J., MULLENIX, R. B. & FEENEY, M. J. (1957). *J. Urol.*, 77, 600.
- SAYEGH, E. S. (1950). *J. Urol.*, 63, 353.
- SAYEGH, E. S. & DIMMETTE, R. M. (1956). *J. Urol.*, 75, 671.
- WEBB, E. A., SMITH, B. A. & PRICE, W. E. (1957). *J. Urol.*, 77, 821.

Acknowledgments

We wish to thank Dr. N. H. Myers and Dr. G. Blaine for their assistance in providing the photomicrofilms from our material and to Dr. William Murray, Director of Medical Services, Southern Rhodesia, for his permission to publish this study.