

# The Central African Journal of Medicine

Volume 18

APRIL, 1972

No. 4

## Smallpox in Rhodesia and the Use of the Electron Microscope in the Diagnosis of This and Other Diseases

BY

R. SWANEPOEL and J. G. CRUICKSHANK

*Department of Microbiology, University of Rhodesia.*

The number of cases of smallpox reported in Rhodesia has fallen from 203 in 1964 to only six in 1970 (Reports of the Secretary for Health, 1964-1970). Owing largely to extensive vaccination programmes and strict surveillance at border posts no urban epidemics have occurred for six years and indeed no cases have been reported from Midlands province for over seven years. This remarkable and gratifying picture has, however, certain self-inflicted consequences.

The main one is that although smallpox is easy enough to recognise during an outbreak or even in an endemic area, sporadic cases are often

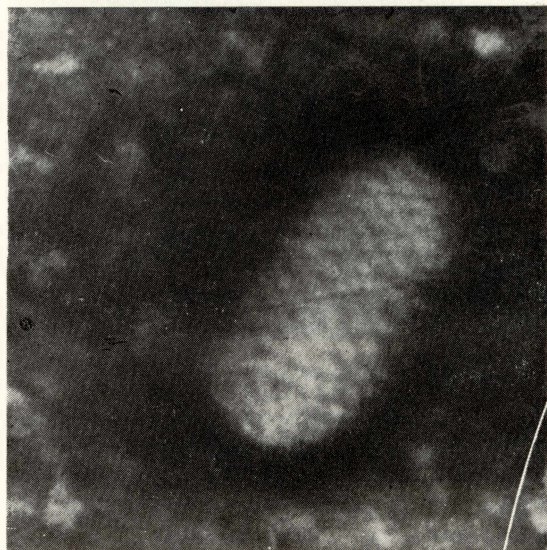

Fig. 2—Orf.

difficult to diagnose. Hence undiagnosed cases may slip through to become the foci of outbreaks while misdiagnosed cases cause alarm and initiate unnecessary and expensive activity on the part of the public health authorities. Paradoxical as it may seem, therefore, the fewer the cases the greater is the importance of establishing the diagnosis accurately in the laboratory.

Until 1969 the diagnosis of smallpox in this country was largely clinical, but since then the communicable diseases section of W.H.O. has expressed a wish to obtain isolates for comparison with others from elsewhere. Consequently a few specimens have been submitted to the virus laboratory at the University for examination and virus isolation. Some of these specimens have been from clinically diagnosed smallpox while others are from cases thought unlikely to be smallpox but in which laboratory confirmation would be desirable.

This paper reports the laboratory findings in these cases to indicate (1) the availability of such a service in Rhodesia; (2) that rapid reporting can be achieved after receipt in the laboratory of the specimen; (3) that rapid positive alternative

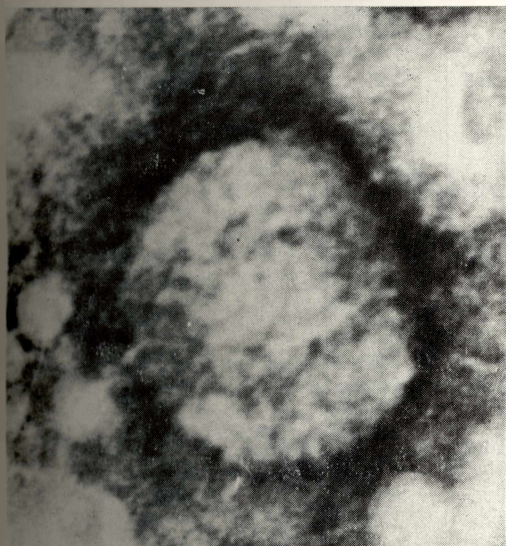

Fig. 1—Smallpox (from case 22-12-70).

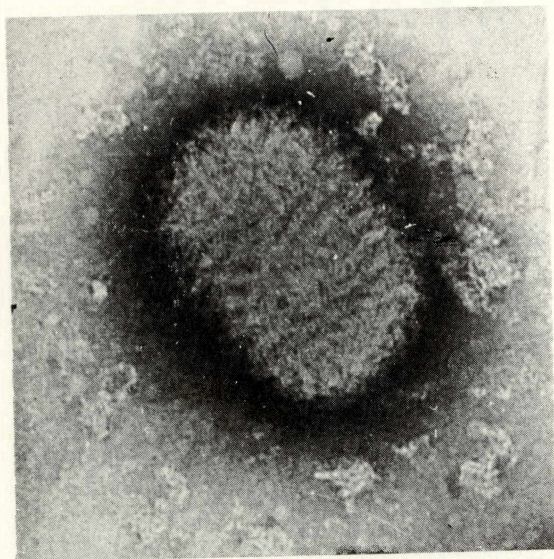


Fig. 3—Molluscum contagiosum.

diagnoses can be established in some cases; and (4) that the diagnosis of smallpox can and should be confirmed in the laboratory in every case, even when the specimen may necessarily take

some days to reach the laboratory.

One technique used in the diagnosis of smallpox is electron-microscopy for virus particles, and some examples of the general usefulness of this technique in medical and veterinary diagnosis in Rhodesia are included in this report.

#### MATERIALS AND METHODS

Smallpox specimens are received in a form according to the stage at which the case is seen.

In the macular or papular stage of the rash, lesions are scraped with a cutting needle or scalpel blade and the fluid which oozes out is smeared on a small area on a microscopic slide. Smears are air-dried and taped face to face with the slides held slightly apart by match sticks.

Smears of vesicle fluid are prepared in similar fashion after puncturing vesicles with a needle or a scalpel blade. In addition, fluid escaping from punctured vesicles is collected by applying the end of a capillary (e.g., micro-haematocrit) tube to the fluid and allowing it to be drawn into the tube by capillary action. Three or four tubes per patient are half or three-quarter filled and shaken so that the fluid lies in the mid-length of the tube. In this way, the fluid is not drawn out when the tubes are placed in a screw-capped universal container.

Table 1

#### SMALLPOX SPECIMENS

#### TESTS/RESULTS

Date Received	Specimen	Clinical Diagnosis	Origin	Immuno-diffusion for variola	Electron Microscopy	Growth in eggs	Comple- ment fixation
13/9/69	Vesicle fluid	Molluscum contagi- osum?	Sby. ex Umtali	Positive	ND	ND	NA
13/10/69	Vesicle fluid	Chickenpox/Small- pox	Salisbury	Negative	ND	ND	NA
10/11/69	Vesicle fluid	Chickenpox/Small- pox?	Nuanetsi	Positive	ND	ND	NA
10/11/69	Pustule smear	Smallpox?	Chibi	NA	ND	Variola	NA
3/4/70	Crust smear	Chickenpox	Bulawayo	NA	Negative	Negative	NA
24/4/70	Crusts	Smallpox?	Filabusi	NA	Negative	Negative	NA
11/8/70	Pustule smear	Chickenpox/Small- pox?	Chiredzi	NA	Herpes	Negative	NA
21/9/70	Vesicle fluid & smear + serum	Smallpox?	Bikita	Negative	Negative	Negative	Negative
1/10/70	'Nodule' smear	Smallpox?	Bulawayo	NA	Negative	Negative	NA
14/10/70	Smear	Chickenpox/Small- pox	Bulawayo	NA	Herpes	Negative	NA
26/10/70	Vesicle smear	Smallpox?	Belingwe	NA	Herpes	Negative	NA
22/12/70	Pustule fluid & serum	Smallpox?	Sby. ex Bindura	Negative	Variola	ND	Negative
16/2/71	Serum	Smallpox	Chipinga	NA	NA	NA	Negative
26/8/71	Crusts	Smallpox	Chipinga	NA	Herpes	Negative	NA

\*1 ND = Not done

\*2 NA = Not applicable



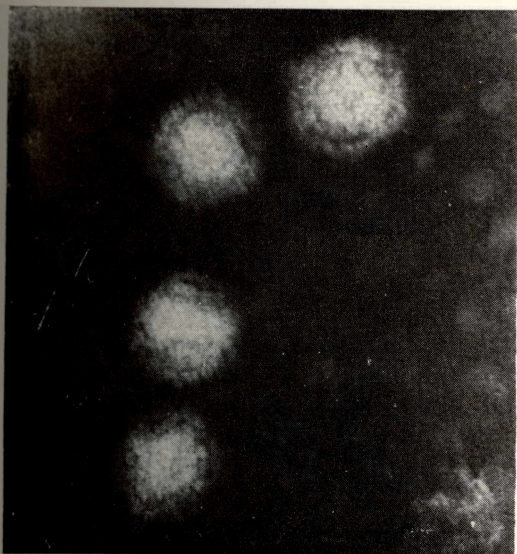


Fig. 4—Herpes simplex.

Pustules are treated as vesicles except that it may be difficult to obtain capillary tube specimens once the lesions begin to shrink. In the crusting stage three or four crusts are removed with forceps and placed in a screw-capped container.

All specimens are sealed into plastic bags and, if possible, placed in a thermos flask with ice. Alternatively they are placed in a cardboard box with absorbent packing. Parcels are labelled "Pathological specimens—urgent" and dispatched by quickest available transport to: The Department of Medical Microbiology, University of Rhodesia, P.O. Box MP 167, Mount Pleasant, Salisbury. Road transport firms have been found to provide very satisfactory service.

The three principal methods used to diagnose smallpox are (i) electron microscopy, (ii) agar gel immunodiffusion for the detection of smallpox antigen and (iii) growth in eggs

*Electron microscopy* is performed on vesicle fluid, or scrapings and smears of skin lesions or on ground crust material. An aqueous emulsion of the specimen is transferred to a copper grid, washed three times in distilled water and negatively stained in two per cent. sodium phosphotungstate at pH 7.4. The grid is dried and placed in the microscope. The process takes approximately three to five minutes. The grid is scanned at about 20 000 times magnification for the presence of virus particles.

*Agar gel immunodiffusion* can be performed on the same types of specimen but is most likely to

be successful with vesicular or pustular fluid. Smallpox virus shares antigens with vaccinia virus and hence antivaccinal serum is used to detect antigen in clinical specimens.

Slides are poured with 3 ml of hot one per cent. Ionagar or Noble agar. After the agar has set, a three-hole pattern is cut, the cups being 4 mm. in diameter with 6.5 mm. centre to centre spacing. Hyperimmune antivaccinal serum is placed in one cup, control positive vaccinia antigen in another and the specimen in the third. The preparation is incubated at room temperature in a damp chamber and examined at two hours and subsequently. Gel diffusion tests usually give a result in two to four hours and certainly overnight.

*Virus isolation* is performed on the chorio-allantoic membrane of the hen's egg. Eggs are examined on the second day and again on the third day when the final report is made.

Electron microscopy for conditions other than smallpox is performed in similar fashion to that detailed above.

## RESULTS

### *Smallpox*

Specimens received with a provisional diagnosis of smallpox are presented in Table I. It is to be noted that the majority of cases reported as smallpox since 1969 have been diagnosed purely clinically and presumably laboratory confirmation was sought only for those cases in which the diagnosis was doubtful. Specimens obtained before 1970 were examined only by gel diffusion

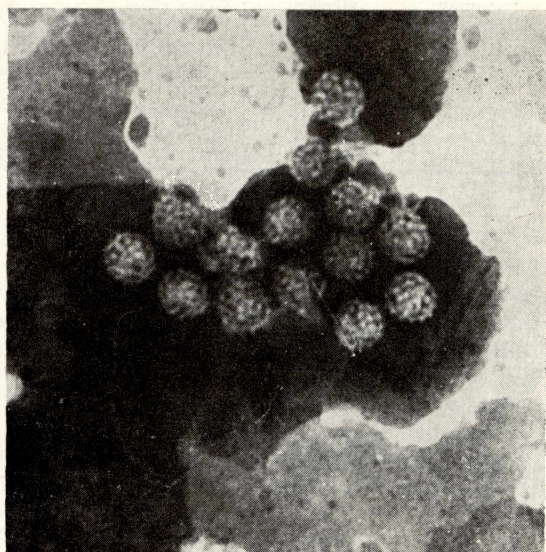


Fig. 5—Human papilloma (verruca vulgaris).

or by growth in eggs, as the electron microscope was not available until February, 1970.

Three of the four specimens examined in 1969 proved to be positive either by gel diffusion or by isolation in eggs. Of the subsequent 11 cases one was shown by electron microscopy to be smallpox (Fig. 1), four specimens contained herpes or herpes-like particles and five showed neither particles in the electron microscope nor growth in eggs.

Complement-fixation tests undertaken in three cases in the hope of making a retrospective diagnosis, were negative. One serum was from a case shown to be smallpox by electron microscopy. This serum, however, had been taken in the acute stage of the disease when a positive result was unlikely.

#### *Other viruses*

Other virus diseases diagnosed by electron microscopy are summarised in Table II.

*Table II*

VIRUSES OTHER THAN SMALLPOX DETECTED  
DIRECTLY IN CLINICAL SPECIMENS BY  
ELECTRON MICROSCOPY

Source	Type of particle	Diagnosis	Figure
Human	Pox	Orf	2
Human	Pox	Molluscum contagiosum	3
Human	Pox	Cowpox	4
Human	Herpes	Herpes simplex	
Human	Herpes	Chickenpox	
Human	Herpes	Zoster	5
Human	Papova	Verruca vulgaris	
Pig	Pox	Pigpox	6
Cattle	Papova	Papilloma	7
Horse	Papova	Papilloma	8
Sheep	Pox	Orf	

#### DISCUSSION

The use of electron microscopy in the diagnosis of smallpox fulfils the criteria of good laboratory procedure—rapidity, simplicity, accuracy and sensitivity. In the 1966 Birmingham outbreak only one case which proved later to be positive was negative by electron microscopy while 40-odd other cases were rapidly confirmed (Cruickshank, Bedson and Watson, 1966). Although it must be borne in mind that vaccinia, cowpox and smallpox virus particles are indistinguishable from one another by electron microscopy, the case history and clinical manifestations usually clarify the diagnosis. Generalised vaccinia is not a natural disease and its occurrence would in all probability

be associated with recent vaccination. Cowpox is an occupational hazard of people working with livestock and it is unlikely to occur in generalised form.

The detection of herpes-like virus particles by electron microscopy allows an alternative diagnosis of chicken pox or generalised herpes-simplex to be established and again the clinical manifestations should make it possible to arrive at a definite diagnosis.

Immunodiffusion has a more restricted application to the vesicular or pustular stages of smallpox and as ordinarily used it does not offer any advance over electron microscopy in distinguishing smallpox from vaccinia. It nevertheless constitutes an inexpensive and rapid aid to diagnosis which could be undertaken by most laboratories.

It is generally accepted that growth in eggs is the most sensitive method for isolating smallpox virus and specimens are always examined by this method irrespective of the results of other tests. The pocks produced on the chorioallantoic membrane of eggs by herpes-simplex, vaccinia, cowpox and smallpox viruses are easily distinguished from each other while the herpes-zoster virus of chickenpox/shingles fails to grow in eggs. Variola minor (Alastrim), variola major and intermediate strains of smallpox virus can be distinguished from each other by the ceiling temperature at which they grow in eggs (Bedson & Dumbell, 1961).

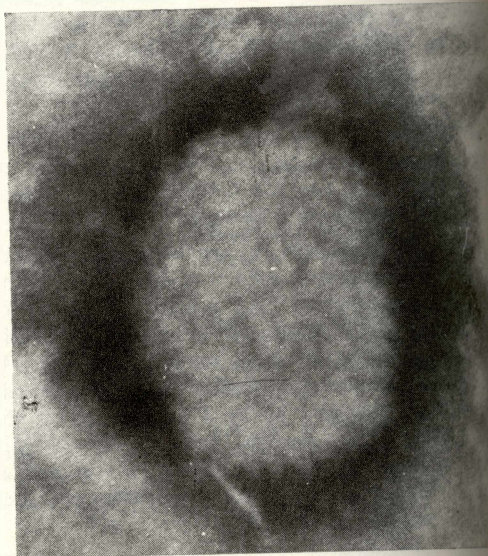


Fig. 6—Pigpox.



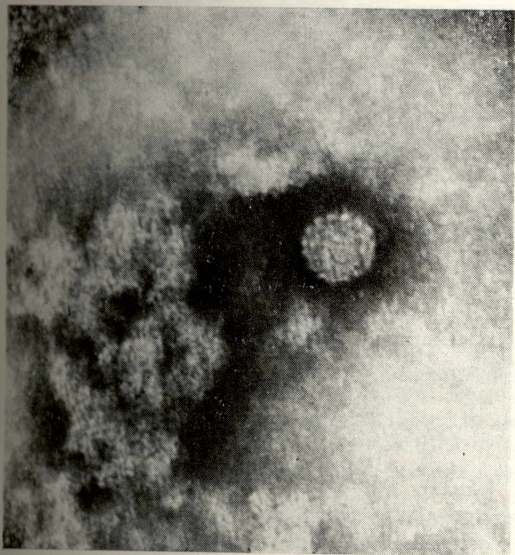


Fig. 7.—Bovine papilloma.

The diagnosis in every case of suspected smallpox should be confirmed in the laboratory. Now that so few cases are seen experience in the clinical diagnosis is decreasing and a generation of practitioners is growing up who have never and may never see the disease. The extensive and expensive measures required to be undertaken to trace the source of an outbreak and to protect the population at risk are such a gross inconvenience to all concerned that an incorrect diagnosis has very far-reaching and adverse consequences. A further reason for laboratory confirmation is the necessity for Rhodesia to play its part in the general world surveillance of this disease. Eradication is in sight and it is important to locate outbreaks rapidly and to identify accurately the type of virus involved; variola major or minor (Official Records, W.H.O. 1970).

Finally, the virus is sufficiently hardy and stable for specimens in the form of smears on slides, vesicular or pustular fluids or crusts to remain usable even after a number of days "on the road". There is thus no reason why specimens should not be submitted from every case no matter how remote geographically it may be. Even from the few cases presented here it is apparent that most cases that are doubtful turn out not to be smallpox.

The general usefulness of the electron microscope in the diagnosis of virus diseases is restricted by the fact that a high concentration of virus particles is required in the clinical specimen

before they can be detected with certainty in the microscope. Specimens from the skin conditions listed in Table II are ideally suited for electron microscopy. Particles are plentiful in lesions from these conditions whether they are papillomatous, papular, vesicular, pustular, ulcerative or crusting and a positive diagnosis can rapidly be made. In some instances, as in the veterinary diseases, there

may be little doubt about the clinical diagnosis, but electron microscopy is nevertheless useful as a visual check on the potency of the autogenous vaccines commonly used in these diseases.

In other diseases electron microscopy is finding increasing use as a means of speeding the process of identifying a virus once it has been grown in cell culture from a clinical specimen (Fig. 9). The problem of the morphological similarity of viruses with widely differing antigenic and pathogenic properties is being overcome by using electron-dense labelled antibodies (immunoferritins) to make possible the specific identification of viruses by electron microscopy. However, further development is required before the technique can be used routinely.

#### SUMMARY

The methods used to examine smallpox specimens in the laboratory are described. Only four out of 14 specimens examined in Rhodesia since 1969 have proved to be positive for smallpox. A further four specimens contained herpes-like virus particles, and in six instances no diagnosis could be confirmed.

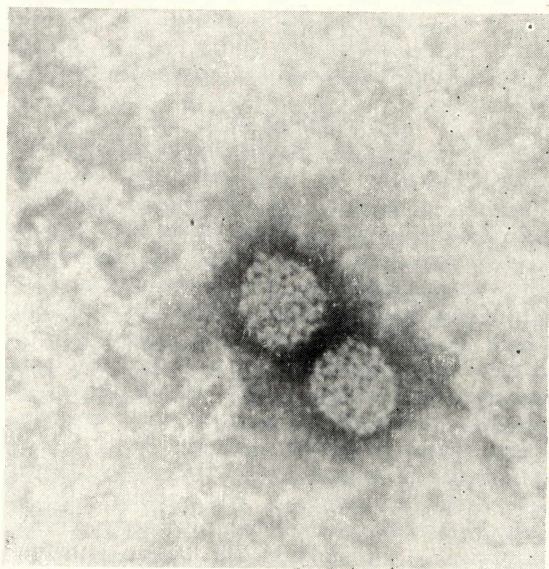


Fig. 8.—Equine papilloma.

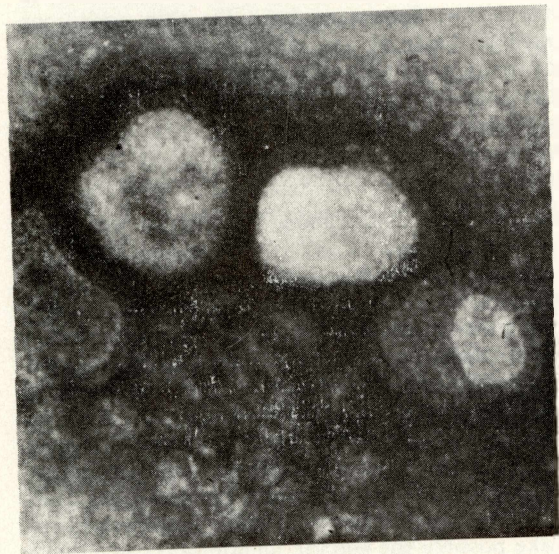


Fig. 9—Rhodesian isolate of Hong Kong influenza.

Now that the disease is so rare it is suggested that the diagnosis in every suspected case should be confirmed in the laboratory and instructions are included for the taking and submission of specimens.

A few examples are given of the usefulness of the electron microscope in the diagnosis of virus diseases other than smallpox, particularly diseases producing skin lesions in man and animals.

#### REFERENCES

- Annual Reports of the Secretary for Health, Rhodesia (1964-1970).
- BEDSON, H. S. & DUMBELL, K. R. (1961). *J. Hyg. Camb* **59**, 457.
- CRUICKSHANK, J. G., BEDSON, H. S. & WATSON, D. S. (1966) *Lancet*, **ii**, 527.
- Official Records of the World Health Organisation No. 188 p. 15. 1970.
- All electron micrographs are at a magnification of about 222 000 X.